

**PRESENTING CLINICAL SIGNS**

History: Recently diagnosed with HW disease. Microfilaria positive. Currently receiving doxycycline and Interceptor.

**DATE**

12/13/21

**ECHOCARDIOGRAPHIC FINDINGS**

2D, M-mode, and Doppler study.

**PERFORMED BY:**

Kelly Vazquez

**INTERPRETED BY**

Keith Blass, DVM,  
MS, DACVIM  
(Cardiology)

Left atrial size is normal. The mitral valve is normal. Left ventricular dimensions are normal. Left ventricular systolic function is normal. The aorta and aortic appear normal, though trace aortic insufficiency is present. Right atrial and right ventricular dimensions are normal. The tricuspid valve is normal. The pulmonary artery and pulmonic valve appear normal, though trace pulmonic insufficiency is present. No heartworms are visualized. No shunting lesions are visualized. No pericardial effusion or cardiac masses are seen.

**PATIENT**

Cocoa Harris

LA - 25.7 mm  
LVIDd - 25.0 mm  
LVIDs - 14.7 mm  
FS - 41%  
RA - 20.1 mm  
LVOT - 1.18 m/s  
RVOT - 0.99 m/s  
PI - 1.80 m/s

**SPECIES**

Canine

**ASSESSMENT/RECOMMENDATIONS**

Normal echocardiogram

**BREED**

Terrier Mix

This examination demonstrates no evidence of structural heart disease, as trace regurgitation of blood across Cocoa's aortic and pulmonic valves can be considered normal physiologic variants. The absence of heartworms in Cocoa's proximal pulmonary arteries and right heart suggests that her worm burden is relatively low, however, strict exercise restriction is still recommended throughout the course of therapy.

**SEX**

FS

No contraindication to heartworm adulticide therapy is seen in this exam following completion of Cocoa's course of doxycycline.

**AGE**

15 mo

A recheck heartworm antigen test is recommended 9 months after the final melarsomine injection. A recheck echocardiogram is recommended if new physical exam and/or clinical abnormalities suggestive of cardiac dysfunction develop.

**WEIGHT**

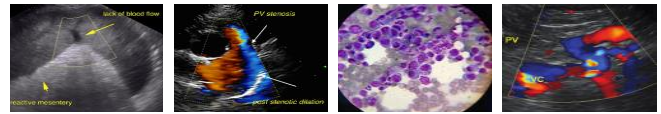
17.4 lb

**HOSPITAL NAME**

Cresskill AH

**REFERRING VET**

Dr. Micale



DATE

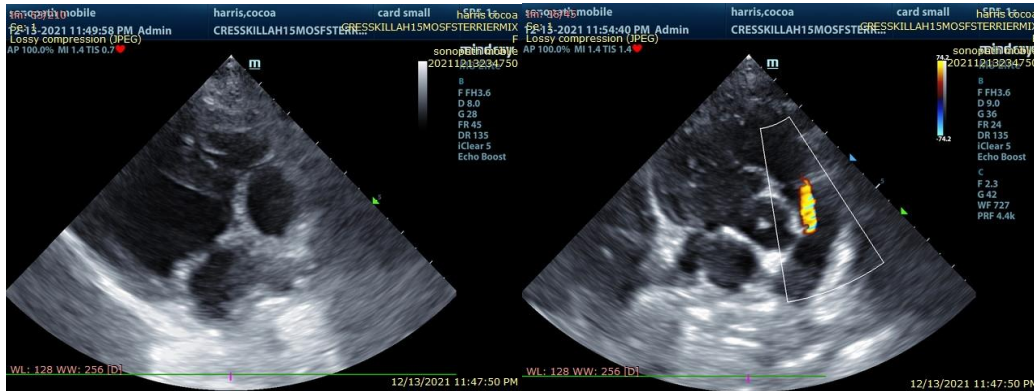
12/13/21

PERFORMED BY:

Kelly Vazquez

INTERPRETED BY

Keith Blass, DVM,  
MS, DACVIM  
(Cardiology)



PATIENT

Cocoa Harris

SPECIES

Canine

BREED

Terrier Mix

SEX

FS

AGE

15 mo

WEIGHT

17.4 lb

HOSPITAL NAME

Cresskill AH

REFERRING VET

Dr. Micale

The information and recommendations provided are based on the images presented by the referring veterinarian. No evaluation can be communicated regarding pathology that was not visible in the image/video clips provided.

Thank you for this referral. If the clinical or image interpretation does not parallel your findings or if I can be of any further assistance please contact me.

Keith Blass, DVM, MS, DACVIM (Cardiology)  
KeithBlass@gmail.com  
631-804-5754